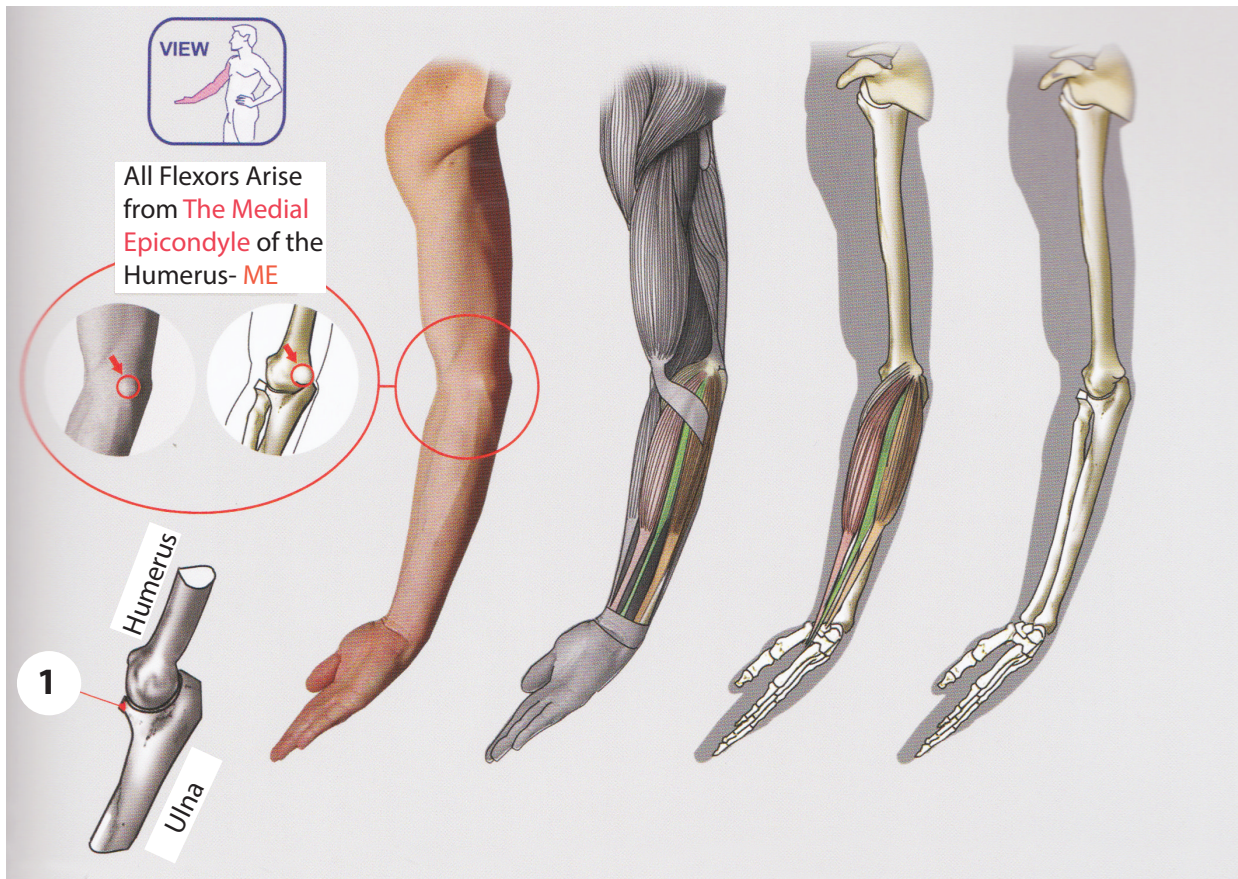


Flexor Muscles



Pronator Teres

Action: Pronation of Forearm, Flexes Elbow

Origin: ME-Medial Epicondyle of Humerus
(Common Flexor Tendon)

1- Ulnar Head:Coronoid process of Ulna

Insertion: **2-** Middle of the Lateral Surface of the Radius

Flexor Carpi Radialis

Action: Flexion and Abduction at the wrist

Origin: ME-Medial Epicondyle of Humerus
(Common Flexor Tendon)

Insertion: **3-** Base of 2nd and 3rd Metacarpal Bones

Palmaris Longus

Action: Flexation of Wrist

Origin: ME-Medial Epicondyle of Humerus
(Common Flexor Tendon)

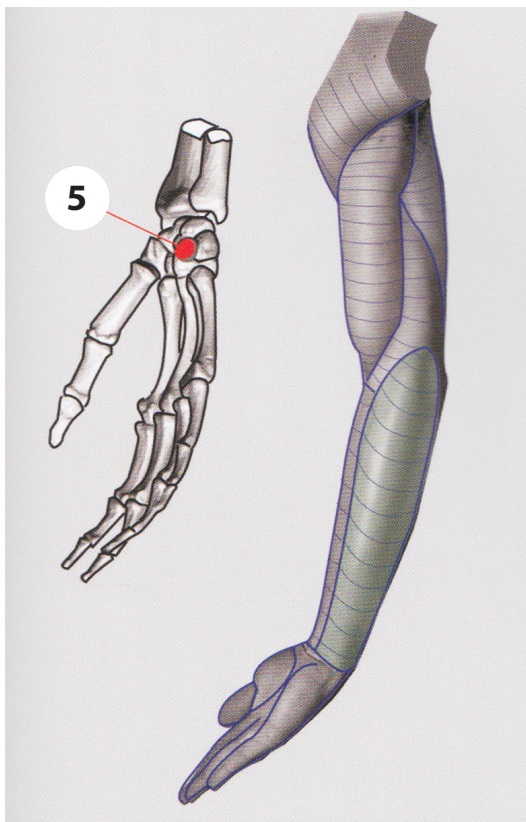
Insertion: **4-** Palmar Aponeurosis

Flexor Carpi Ulnaris

Action: Flexion and Abduction at the wrist

Origin: ME- Medial Epicondyle of Humerus
(Common Flexor Tendon)

Insertion: **5-** Pisiform



Flexor Muscles

